



## Performance and Interpretation of Sonography in the Practice of Nephrology: Core Curriculum 2024

Vandana Dua Niyar, Daniel W. Ross, and W. Charles O'Neill

Ultrasonography is increasingly being performed by clinicians at the point of care, and nephrologists are no exception. This Core Curriculum illustrates how ultrasonography can be incorporated into clinical decision making across the spectrum of kidney disease to optimize the care nephrologists provide to patients. Sonography is valuable in outpatient and inpatient settings for the diagnosis and management of acute and chronic kidney disease, evaluation of cystic disease, urinary obstruction, pain, hematuria, proteinuria, assessment of volume status, and in providing guidance for kidney biopsy. As kidney disease advances, ultrasound is useful in the placement and maintenance of temporary and permanent access for dialysis. After kidney transplantation, ultrasonography is critical for evaluation of allograft dysfunction and for biopsies. Sonography skills expedite patient care and enhance the practice of nephrology and are relatively easily acquired with training. It is our hope that this curriculum will encourage nephrologists to learn and apply this valuable skill.

Complete author and article information provided before references.

*Am J Kidney Dis.* 83(4):531-545. Published online December 15, 2023.

doi: [10.1053/j.ajkd.2023.09.006](https://doi.org/10.1053/j.ajkd.2023.09.006)

© 2023 by the National Kidney Foundation, Inc.

### Introduction

Ultrasound use has important applications for patients with kidney disease throughout their clinical course. Incorporation of sonography into the constantly evolving practice of nephrology has substantial benefits for both patients and clinicians. It provides continuity across diagnosis and management, reduces fragmentation of care, maximizes physician efficiency, and enhances patient convenience. Furthermore, the ability of nephrologists to provide immediate clinical correlation improves the interpretation of sonograms. In addition to limited studies done as an adjunct to the physical examination to assess volume status or to guide procedures such as kidney biopsy and cannulation of dialysis access, ultrasonography performed or interpreted by clinicians at the “point of care” also includes detailed comprehensive diagnostic examinations of the kidneys and urinary tract. This core curriculum will highlight the utility of point-of-care ultrasonography (POCUS) in the practice of nephrology using a case-based format. In keeping with the educational focus of AJKD’s Core Curriculum in Nephrology series, the content of this article emphasizes key concepts of the utility of ultrasonography in the practice of nephrology and its value in making real-world decisions in the clinical setting. It is our hope that this curriculum will encourage nephrologists to learn and apply this valuable skill.

### Sonography in Assessment of Cystic Kidney Diseases

**Case 1:** A 42-year-old man is referred to you for a serum creatinine of 1.8 mg/dL. Other than hypertension, his history is unremarkable, and no family members have kidney disease. You perform a sonogram and obtain the following longitudinal and transverse images of the right kidney (Fig 1). The length is approximately 16 cm. The left kidney has a similar appearance. The sonogram shows numerous anechoic structures consistent with fluid. The absence of any interconnections (more apparent during the examination) indicates a multicystic disorder rather than hydronephrosis.

**Question 1:** Which of the following ultrasound findings is most suggestive of autosomal dominant polycystic kidney disease (ADPKD)?

- Kidney size
- The size of the cysts
- The distribution of the cysts
- Kidney size and the presence of liver cysts

For the answer to this question, see the following text.

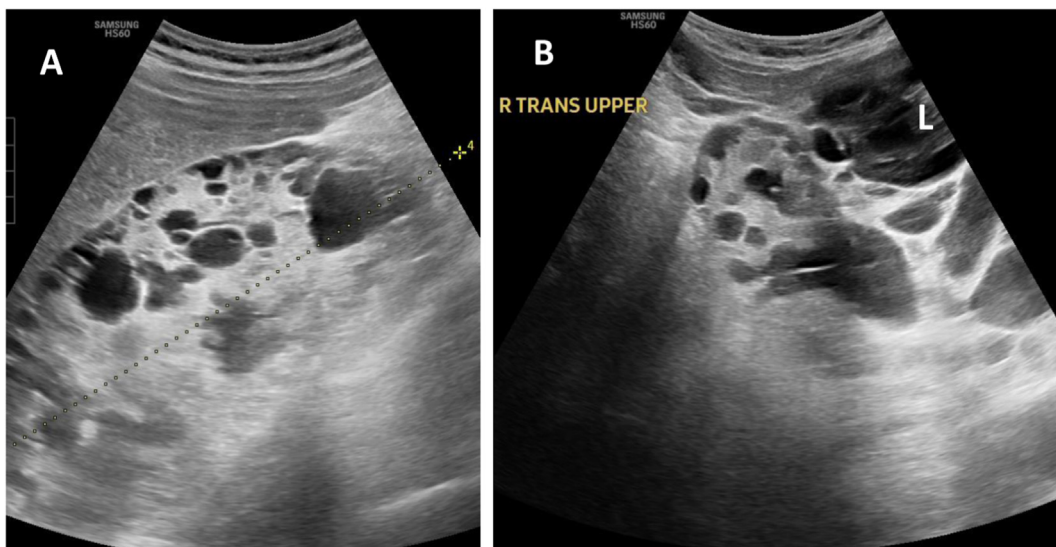
The multiple bilateral cysts with renal enlargement are highly suggestive of ADPKD, but there are other disorders associated with multiple renal cysts and enlarged kidneys, including von Hippel-Lindau disease and tuberous sclerosis. Absence of renal enlargement would suggest an alternative diagnosis, specifically acquired cystic kidney disease associated with advanced chronic kidney disease

**FEATURE EDITOR**  
Melanie Hoenig

### ADVISORY BOARD

Ursula C. Brewster  
Michael J. Choi  
Biff F. Palmer  
Bessie Young

The Core Curriculum aims to give trainees in nephrology a strong knowledge base in core topics in the specialty by providing an overview of the topic and citing key references, including the foundational literature that led to current clinical approaches.



**Figure 1.** (A) Longitudinal image of the right kidney showing multiple cysts. (B) Transverse image of the right kidney showing cysts in the liver (L) in addition to the renal cysts.

(CKD). Although the kidneys can sometimes be enlarged in acquired cystic kidney disease, it is almost never to this extent.

Measurement of kidney size in ADPKD is important in determining prognosis, with lengths over 16 cm associated with more rapid progression. Kidney length can be difficult to measure because the kidneys usually extend beyond the sector of the probe. However, it can be accurate enough to provide prognostic information and follow progression.

Involvement of both kidneys eliminates unilateral disorders such as multicystic dysplastic kidney, but cysts can often be unilateral in very early ADPKD, and some patients (<1%) can have unilateral disease due to mosaicism. The cysts in ADPKD can range from very small to very large, and therefore size of the cysts is not helpful in diagnosing ADPKD. Although the cysts in ADPKD are cortical, they can fill the kidney as the disease progresses, distorting the architecture and appearing to arise from any portion of the kidney.

Hepatic cysts are very common in ADPKD, but they are rare in other cystic disorders. These are apparent in the transverse image (Fig 1B) where the liver is to the right and slightly superior to the kidney. Thus, the combination of renal enlargement and hepatic cysts is strongly suggestive of ADPKD. However, the absence of hepatic cysts does not rule out ADPKD. Thus, the correct answer is (d), kidney size and the presence of liver cysts.

ADPKD is one of the most common genetic disorders and is frequently encountered in outpatient nephrology practice. Given the importance of sonography in the management of this and other cystic disorders, performance of sonograms in the office or clinic greatly expedites and enhances patient management.

### Additional Readings

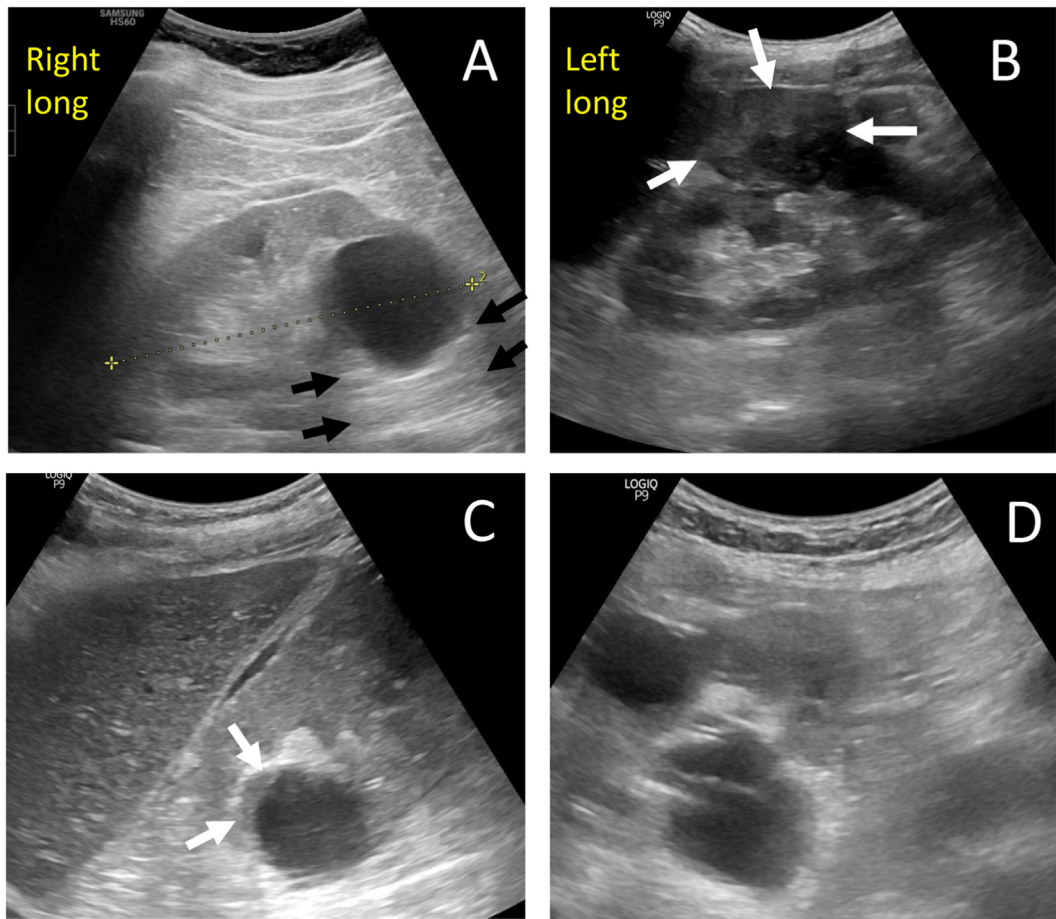
- Bhutani H, Smith V, Rahbari-Oskoui F, et al. A comparison of ultrasound and magnetic resonance imaging shows that kidney length predicts chronic kidney disease in autosomal dominant polycystic kidney disease. *Kidney Int.* 2015;88(1):146-151. doi:10.1038/ki.2015.71
- Pei Y, Obaji J, Dupuis A, et al. Unified criteria for ultrasonographic diagnosis of ADPKD. *J Am Soc Nephrol.* 2009;20(1):205-212. doi:10.1681/asn.2008050507 ★ESSENTIAL READING
- Ravine D, Gibson RN, Walker RG, Sheffield LJ, Kincaid-Smith P, Danks DM. Evaluation of ultrasonographic diagnostic criteria for autosomal dominant polycystic kidney disease 1. *Lancet.* 1994;343(8901):824-827. doi:10.1016/s0140-6736(94)92026-5

**Case 2:** A 60-year-old man presents for evaluation of CKD. His history is positive only for long-standing hypertension. His serum creatinine level is 1.9 mg/dL. He reports no urinary symptoms, hematuria, weight loss, or flank pain. Figure 2A and B shows the images obtained during a sonogram performed in the clinic.

### Question 2: Concerning the interpretation of these images, which of the following is true?

- (a) There is a solid mass in each kidney.
- (b) There is a simple cyst in each kidney.
- (c) There is a simple cyst in the right kidney and a solid mass in the left kidney.
- (d) There is a complex cyst in the right kidney and a solid mass in the left kidney.

For the answer to this question, see the following text.



**Figure 2.** (A) Longitudinal image of the right kidney showing an anechoic simple cyst with posterior enhancement (black arrows). (B) Longitudinal image of the left kidney showing solid mass with heterogeneous echogenicity. (C) Image from a different patient showing irregularities in the cyst wall. (D) Complex cyst with thick septations and internal echoes in another patient.

The lesion in the right kidney has all the features of a simple cyst: it is anechoic with a smooth wall and posterior enhancement (Fig 2A, arrows). By contrast, the mass in the left kidney (Fig 2B, arrows) appears solid, has heterogeneous echogenicity, and demonstrates no posterior enhancement. Posterior enhancement can be seen in both simple and complex cysts and is highly specific for the presence of fluid. It occurs due to the lack of attenuation of sound by the cyst fluid compared with the surrounding structures. As illustrated in images from different patients, complex cysts may have irregularities in the wall (Fig 2C) or thick septations and internal echoes (Fig 2D).

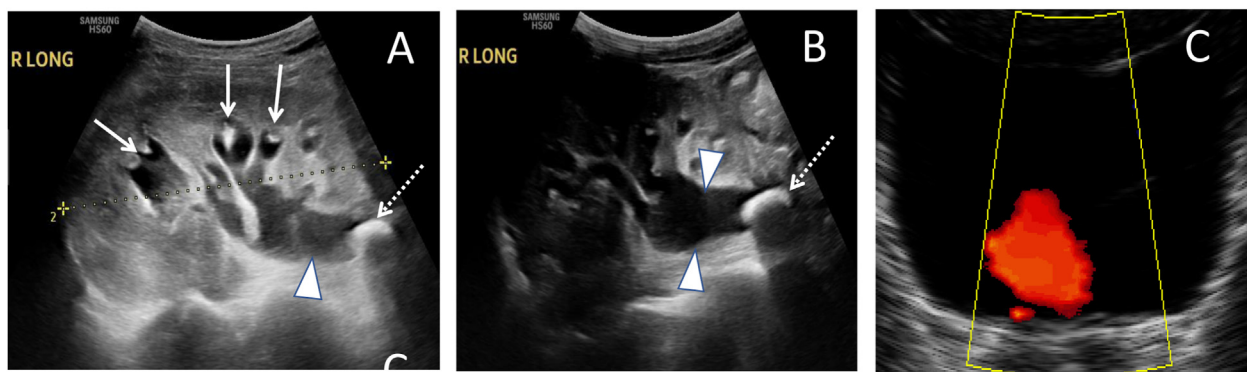
A simple cyst identified by sonography does not require any further evaluation or follow-up. Although the vast majority are benign, complex cysts require follow-up, often just by sonography but also by other modalities, depending on the appearance and clinical situation. Solid masses require additional imaging because sonography cannot distinguish between benign and malignant masses. Thus, the correct answer is (c), there is a simple cyst in the right kidney and a solid mass in the left kidney.

### Additional Readings

- Fried JG, Morgan MA. Renal imaging: core curriculum 2019. *Am J Kidney Dis.* 2019;73(4):552-565. doi:10.1053/j.ajkd.2018.12.029
- O'Neill WC. *Atlas of Renal Ultrasonography.* W.B. Saunders; 2000.
- Pollack HM, Banner MP, Arger PH, Peters J, Mulhern CB, Coleman BG. The accuracy of gray-scale renal ultrasonography in differentiating cystic neoplasm from benign cysts. *Radiology.* 1982;143(3):741-745. doi:10.1148/radiology.143.3.7079503

### Sonography in Assessment of Kidney Dysfunction

**Case 3:** A 75-year-old man is referred to the nephrology clinic for evaluation of kidney disease. His kidney function was normal 9 months ago, but now his serum creatinine level is 1.5 mg/dL. He has no history of hypertension or diabetes and no complaints of hesitancy, flank pain, or dysuria. Physical examination revealed only peripheral edema. A sonogram was performed during the visit (Fig 3) and



**Figure 3.** (A and B) Longitudinal images of right kidney showing dilated calyces (arrows), proximal ureter (arrowheads), and a stone obstructing the proximal ureter (dotted arrows). (C) Transverse image of the bladder with color Doppler showing a ureteral jet emanating from the left ureter.

revealed hydronephrosis of the right kidney. The left kidney appears normal.

**Question 3: Which of the following statements is true regarding the sonographic images of this patient?**

- (a) The hydronephrosis is chronic.
- (b) There is obstruction of the proximal ureter.
- (c) The cause of the hydronephrosis is not apparent from these images.
- (d) Examination of the bladder is not required in unilateral obstruction.

For the answer to this question, see the following text.

There is dilatation of the minor calyces and the proximal ureter (Fig 3A and B). The ureter terminates in an echogenic focus casting an acoustic shadow, indicative of an obstructing stone. There is a significant amount of tissue between the minor calyces and the kidney border, indicating the lack of atrophy that would be indicative of chronic hydronephrosis. Examination of the bladder is mandatory in all cases of hydronephrosis. In particular, demonstrating ureteral jets, the result of pulses of urine traveling down the ureter, can aid in establishing that a ureter is not obstructed. These are best demonstrated with Doppler; in this case, jets were observed from the left ureter (Fig 3C) but not the right. Thus, the correct answer is (b), there is obstruction of the proximal ureter.

This case illustrates the importance of performing a sonogram of the kidneys and bladder on every patient with unexplained kidney failure. Urinary obstruction is frequently asymptomatic, and kidney stones are not always painful. Performance of the sonogram at the time of the initial evaluation expedited the care of this patient and resulted in immediate urological referral.

**Sonography in Assessment of Chronic Kidney Disease**

**Case 4:** A 54-year-old woman is referred to you for a serum creatinine level of 2.1 mg/dL and evaluation of hematuria and

proteinuria. She reports a normal creatinine level several years ago and a history of well-controlled hypertension. Her mother had CKD. The history is otherwise unremarkable. On the sonogram you perform, the cortical echogenicity is normal, a measurement of the right kidney yields a length of 9.2 cm and a measurement of the left kidney yields a length of 9.5 cm.

**Question 4: What parameter is the most specific for assessing the presence of advanced CKD?**

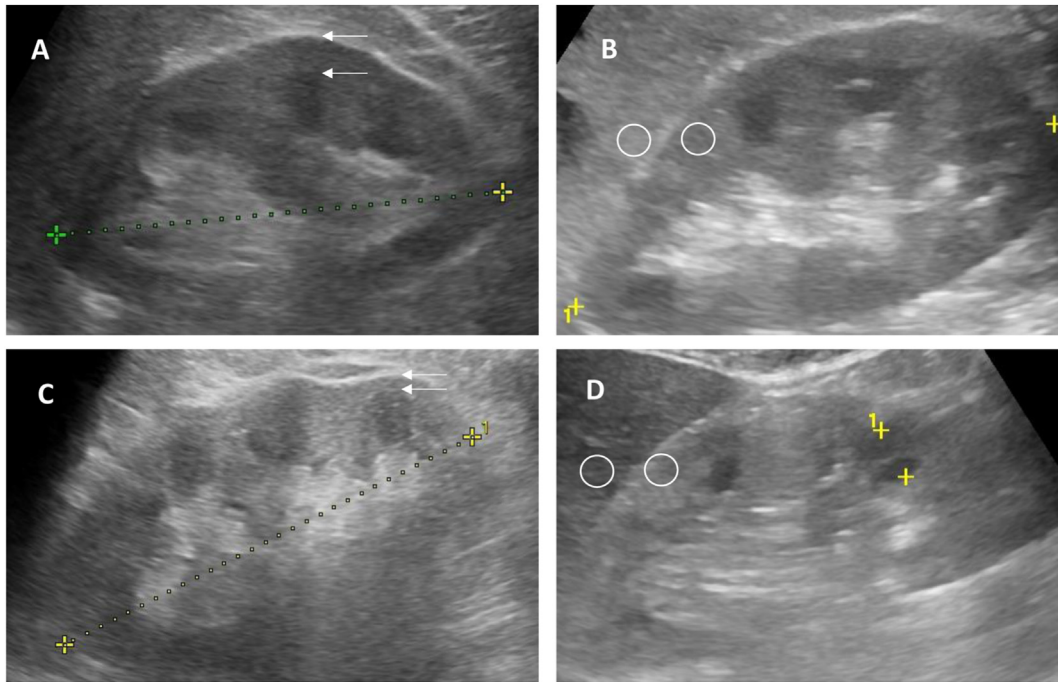
- (a) Kidney length
- (b) Cortical thickness
- (c) Cortical echogenicity
- (d) Doppler measurement of resistive index

For the answer to this question, see the following text.

Small kidney size is a common finding in CKD but lacks sensitivity and specificity. Considering the importance of kidney size in clinical decisions, it is critical that it be measured accurately because oblique scanning will yield falsely shorter lengths. Thus, it is the maximum length obtained from several measurements that best approximates the true length. The recommended protocol is to repeat the measurements at least 3 times. Other dimensions (width and depth) are very inaccurate, are poorly reproducible, and do not add any useful information.

Kidney size varies with body size, more specifically with lean body mass, which is best approximated by body height and is larger in men independent of body size. Thus, kidney lengths below 10 cm are common in smaller persons but would likely represent CKD in larger persons. However, because there is a wide range of normal kidney lengths for a given body height, length alone should not be used as the sole sonographic criterion for advanced CKD.

Reduced cortical thickness (normally 7-9 mm) is a more specific indicator for CKD. It should be measured from the base of a medullary pyramid to the edge of the kidney at the midkidney because thickness is greater at the poles; it was



**Figure 4.** (A and B) Longitudinal images of right kidney. The cortical thickness, measured from the base of a pyramid to the edge of the kidney (arrows), is 8 mm and the cortical echogenicity is less than that of the liver at the same depth (circles). (C). Longitudinal image from a different patient showing cortical thinning (3 mm). (D) Increased cortical echogenicity in another patient. Note the normal cortical thickness.

normal in this patient (Fig 4A). By contrast, the cortex is thin in Figure 4C (image taken from another patient), and this often enhances the lobulation of the cortex, as seen in this image.

The echogenicity of the cortex should be less than that of the adjacent liver or spleen at the same depth, as it was in this patient (Fig 4B), but this is subject to artifacts and the fact that liver echogenicity can be abnormal. Increased echogenicity is sometimes erroneously ascribed to fibrosis but is not specific for CKD and can be normal in advanced CKD and increased in acute, reversible acute kidney injury. Increased echogenicity can lead to prominence of the medullary pyramids. Resistive index is primarily determined by extrarenal factors and is rarely of any utility in renal sonography. Thus, reservations about performing and interpreting Doppler studies should not deter nephrologists from performing sonograms. Thus, the correct answer is (b), cortical thickness.

### Sonography in Guidance for Kidney Biopsy

**Case 4, continued:** A renal biopsy was considered in order to make a histologic diagnosis.

#### Question 5: Which of the following is true regarding kidney biopsy in this patient?

- (a) The kidney size in this patient precludes a kidney biopsy.
- (b) A computed tomography (CT)-directed biopsy would be safer than an ultrasound-guided biopsy.

- (c) The biopsy needle may be poorly visualized by ultrasound.
- (d) Real-time imaging is required for this ultrasound-guided biopsy.

*For the answer to this question, see the following text.*

Although her kidneys are small, their size is within the normal range for a woman of her body size, and the cortical thickness is as expected. These findings make it likely that there is not extensive irreversible disease. So it is reasonable to proceed to biopsy in this patient.

Biopsies of kidneys such as in Figure 4C rarely reveal treatable disease. Published data show similar success and complication rates for biopsies guided by ultrasound or CT. Needles are specular reflectors that direct most of the sound away from the probe when insonated at an angle and thus are not well detected. Because of this and the need to maintain the needle within the narrow sound beam, biopsies performed under direct imaging (real-time guidance) can be more difficult, and they are not necessarily safer than marking the kidney ahead of time. The correct answer is (c), the biopsy needle may be poorly visualized by ultrasound.

A renal biopsy was successfully performed at the bedside by the nephrology service, yielding a diagnosis of IgA nephropathy. In published series, ultrasound-guided biopsies performed by nephrologists have shown success

rates, glomerular yields, and complication rates that are similar to or better than other published data, including CT-directed biopsies. These 2 cases demonstrate the importance of sonography in the evaluation of kidney disease and how performance by the nephrologist can enhance patient care.

### Additional Readings

- Johnson S, Rishi R, Andone A, et al. Determinants and functional significance of renal parenchymal volume in adults. *Clin J Am Soc Nephrol*. 2011;6(1):70-76. doi:10.2215/CJN.00030110
- Moghazi S, Jones E, Schroeppe J, Arya K, McClellan W, Neill WC. Correlation between renal histopathology and sonographic findings. *Kidney Int*. 2005;67:1515-1520. doi:10.1111/j.1523-1755.2005.00230.x
- Niyyar VD, O'Neill WC. Point of care ultrasound in the practice of nephrology. *Kidney Int*. 2018;93(5):1052-1059. doi:10.1016/j.kint.2017.11.032
- Palacherla J, O'Neill WC. Point-of-care ultrasound for native kidney biopsies. *Kidney360*. 2020;1(6):527-529. doi:10.34067/KID.0001962020
- Tøndel C, Vikse BE, Bostad L, Svarstad E. Safety and complications of percutaneous kidney biopsies in 715 children and 8573 adults in Norway 1988-2010. *Clin J Am Soc Nephrol*. 2012;7(10):1591-1597. doi:10.2215/CJN.02150212

### Sonography in Preoperative Vascular Mapping

**Case 5:** You have been treating a patient with advanced CKD. Despite appropriate therapy, the patient's kidney function progressively worsens, and you discuss different modalities for replacing kidney function. She is wait-listed for a transplant; in the interim, she chooses to start with in-center hemodialysis. Preoperative vascular mapping is performed, and you review the results with the vascular surgeon and interventionalist. Her arterial and venous diameters on ultrasound on her nondominant arm are as follows: radial artery at wrist, 2.2 mm; ulnar artery, 2.0 mm; proximal radial artery, 4.2 mm; brachial artery, 5.2 mm; cephalic vein at wrist, 2.6 mm; perforating vein in forearm, 3.1 mm; cephalic vein at elbow, 3.3 mm; and basilic vein at elbow, 4.9 mm (Fig 5). The veins are patent and compressible throughout their observed course.

**Question 6:** Which of the following statements is correct about her hemodialysis access options?

- (a) A surgical radiocephalic arteriovenous fistula (AVF) in the distal wrist should be the first choice of access.
- (b) A percutaneous proximal radial artery AVF in the upper forearm should be the first choice of access.
- (c) A brachiocephalic AVF in the upper arm should be the first choice of access.
- (d) She does not have veins suitable for an AVF, and an arteriovenous graft should be the first choice of access.

For the answer to this question, see the following text.

Ultrasound evaluation of the peripheral arteries and veins before AVF creation is noninvasive and avoids exposure to radiation or potentially nephrotoxic contrast as compared to venograms. Preliminary assessment of the vasculature is performed on B-mode imaging and is a skill that can be easily learned and performed by nephrologists. A more detailed and comprehensive vascular mapping before access placement is usually performed by certified vascular sonographers. Irrespective of who performs the procedure, nephrologists, as the leaders of the multidisciplinary team taking care of the complex dialysis patient, should be able to accurately interpret these results and advocate for the optimal access for each patient.

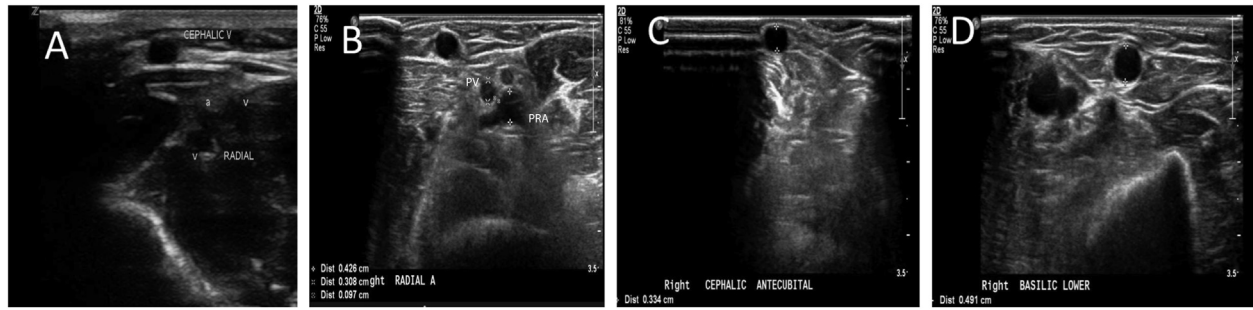
Sonography provides objective morphological and functional assessment of the vasculature including the diameter and depth of the vessels from the skin surface and helps to guide procedural decisions including placement and need for superficialization. However, given the lack of high-quality evidence of preoperative vascular mapping on fistula outcomes, the recently updated K-DOQI guidelines recommend selective preoperative vascular mapping for those patients who are at high risk for AV access failure. These include patients in whom a detailed physical examination is not possible or feasible (eg, morbid obesity), older age, women, those with associated comorbidities like peripheral vascular disease, coronary artery disease, and patients with a history of peripheral vessel damage or central venous stenosis.

By convention, an arterial diameter of 2.0 mm or greater and a venous diameter of 2.5 mm or greater at the site of the expected surgical anastomosis are considered adequate to provide enough blood flow to allow development of a physiologically mature fistula. Vascular mapping for percutaneous AVF includes additional measurements. Both the proximal radial artery and the perforator vein at the planned endovascular anastomosis site should be at least 2 mm in diameter, and the distance between them should be less than 1.5 mm. Of note, the updated guidelines do not define absolute minimal vein and arterial diameter thresholds that prohibit AVF creation. They recommend vessels smaller than 2 mm in diameter should have further careful evaluation for feasibility and quality, including size, distensibility, and flow.

In general, access placement should start with the most distal site and a surgical wrist-based distal radiocephalic or snuffbox fistula still remains the first access of choice, if feasible (as it is in this patient). Thus, the correct answer is (a), a surgical radiocephalic AVF in the distal wrist should be the first choice of access.

### Additional Readings

- AIUM practice parameter for the performance of ultrasound vascular mapping for preoperative planning of dialysis access. *J Ultrasound Med*. 2016;35(9):1-10. doi:10.7863/ultra.35.9.1-a ★ESSENTIAL READING



**Figure 5.** Ultrasound vascular mapping images. (A) Radial artery and cephalic vein at the wrist. (B) Proximal radial artery (PRA) and perforating vein (PV) in close proximity. (C) Cephalic vein at the elbow. (D) Basilic vein at the elbow.

- Lok CE, Huber TS, Lee T, et al. KDOQI clinical practice guideline for vascular access: 2019 update. *Am J Kidney Dis.* 2020;75(4)(suppl 2):S1-S164. doi:10.1053/ajkd.2019.12.001 ★ESSENTIAL READING
- Malovrh M. Native arteriovenous fistula: preoperative evaluation. *Am J Kidney Dis.* 2002;39(6):1218-1225. doi:10.1053/ajkd.2002.33394
- Silva MB Jr, Hobson RW 2nd, Pappas PJ, et al. A strategy for increasing use of autogenous hemodialysis access procedures: impact of preoperative noninvasive evaluation. *J Vasc Surg.* 1998;27(2):302-207 [discussion 307-308]. doi:10.1016/s0741-5214(9870360-x)

### Sonography in Evaluation of Dialysis Access for Maturity

**Case 5, continued:** A distal wrist radiocephalic AVF is placed. On physical examination at the 6-week post-operative visit, the AVF has a pulsatile thrill near the anastomosis that fades proximally. On occlusion of the access proximally, the fistula does not augment. There are no visible accessory veins. You perform an ultrasound to confirm your clinical diagnosis and find the following: a depth of 2 mm, a diameter of 3.5 mm, and a straight segment cannulation length of 8 cm.

**Question 7: Which of the following indicates that the fistula may not be adequate?**

- (a) The depth
- (b) The diameter
- (c) The length
- (d) All the parameters indicate a high likelihood of success

For the answer to this question, see the following text.

Point-of-care B-mode ultrasound assessment of a maturing access, performed as an adjunct to physical examination, provides useful clinical and actionable information. Accurate Doppler flow measurements are more complex to obtain, and most handheld devices do not yet have the capability. The widely used “rule of 6s” describes ultrasound criteria for a physiologically mature AVF that include a vessel diameter of 6 mm, a depth of less than

6 mm from the surface of the skin, an access flow volume of 600 mL/min, and a 6-10 cm straight segment for cannulation; this is derived from a retrospective review that demonstrated that the likelihood of successful fistula cannulation for dialysis was 95% if the access blood flow was at least 500 mL/min and the diameter was at least 4 mm, and 33% if neither of the criteria were met. The correct answer is (b), the diameter.

**Case 5, continued:** You refer the patient to your interventional colleague who performs a juxta-anastomotic angioplasty. The repeat physical and ultrasound examination in 4 weeks shows a mature AVF that is then successfully cannulated.

### Additional Readings

- Robbin ML, Chamberlain NE, Lockhart ME, et al. Hemodialysis arteriovenous fistula maturity: US evaluation. *Radiology.* 2002;225(1):59-64. doi:10.1148/radiol.2251011367 ★ESSENTIAL READING
- Robbin ML, Greene T, Allon M, et al. Prediction of arteriovenous fistula clinical maturation from post-operative ultrasound measurements: findings from the hemodialysis fistula maturation study. *J Am Soc Nephrol.* 2018;29(11):2735-2744. doi:10.1681/ASN.2017111225

### Sonography in Assessment of Hemodialysis Vascular Access

**Case 6:** You are rounding in the dialysis unit and see a new patient who recently moved from another state. He has been on dialysis for >10 years and has a left upper extremity brachiocephalic fistula that has been used for hemodialysis for the last 6 years. He states that he has had problems with it in the past and has had to have it “cleaned out” multiple times. The dialysis staff are having difficulty with cannulation and have already had 2 unsuccessful sticks. Physical examination of the fistula shows an enlarged and tortuous access that does not collapse on arm elevation. There is a scar on the chest from a previous tunneled catheter site. His arm is not swollen, and there are no collaterals on the chest wall. You perform a POCUS to evaluate the access.

**Question 8: Which of the following statements is correct regarding sonographic assessment of this patient's dialysis access?**

- (a) Sonography of his dialysis access is a difficult examination that requires extensive training.
- (b) Sonography is the preferred method to detect central vein stenoses in this patient.
- (c) Sonographic assessment is not useful with him because he has a fistula rather than a graft.
- (d) Ultrasound-guided cannulation may facilitate cannulation and minimize infiltrations in this patient.

For the answer to this question, see the following text.

Ultrasound evaluation of the hemodialysis access by nephrologists is a skill that can be learned relatively easily and helps expedite management of a dysfunctional access as well as determine access maturity and suitability for cannulation. A quick B-mode assessment can be performed at the point of care in outpatient clinics for patients with CKD who are not receiving dialysis, and at hemodialysis centers for those patients who may already be on dialysis with a central venous catheter and a maturing access. The intraluminal diameter, depth from the surface of the skin, accessory or collateral veins and tortuosity can be easily assessed by physical examination and sonography at the bedside.

Sonography at the point of care can also help evaluate arteriovenous grafts, which are typically differentiated from fistulas by parallel echogenic lines, for cannulation guidance if they are deep and to assess pseudoaneurysms and fluid collections. A thrombosed access can also be rapidly identified at the bedside, which avoids inadvertent and unsuccessful cannulation attempts. Figure 6 illustrates some representative ultrasound images of AVFs and arteriovenous grafts. Direct visualization of central veins by ultrasonography is suboptimal. Indirect measures of stenosis such as abnormal waveforms of cardiac pulsatility or respiratory phasicity, especially in patients with a history of central venous catheter use, should be further evaluated by angiography, CT, or magnetic resonance imaging.

Cannulation injuries resulting in major infiltrations are more common during the first 6 months of a newly placed access. Protocols using ultrasound-guided cannulation have been developed in some centers to mitigate this complication and have been successful in decreasing the infiltration rates in those centers. Randomized controlled trials are currently in progress to study the long-term impact and effectiveness of ultrasound-guided cannulation on patient outcomes. Thus, the correct answer is (d), ultrasound-guided cannulation may facilitate cannulation and minimize infiltrations in this patient.

You detect a stent in the aneurysmal portion of the fistula (Fig 6F) and mark the fistula proximal to the stent for cannulation. Hemodialysis is successfully performed.

**Additional Readings**

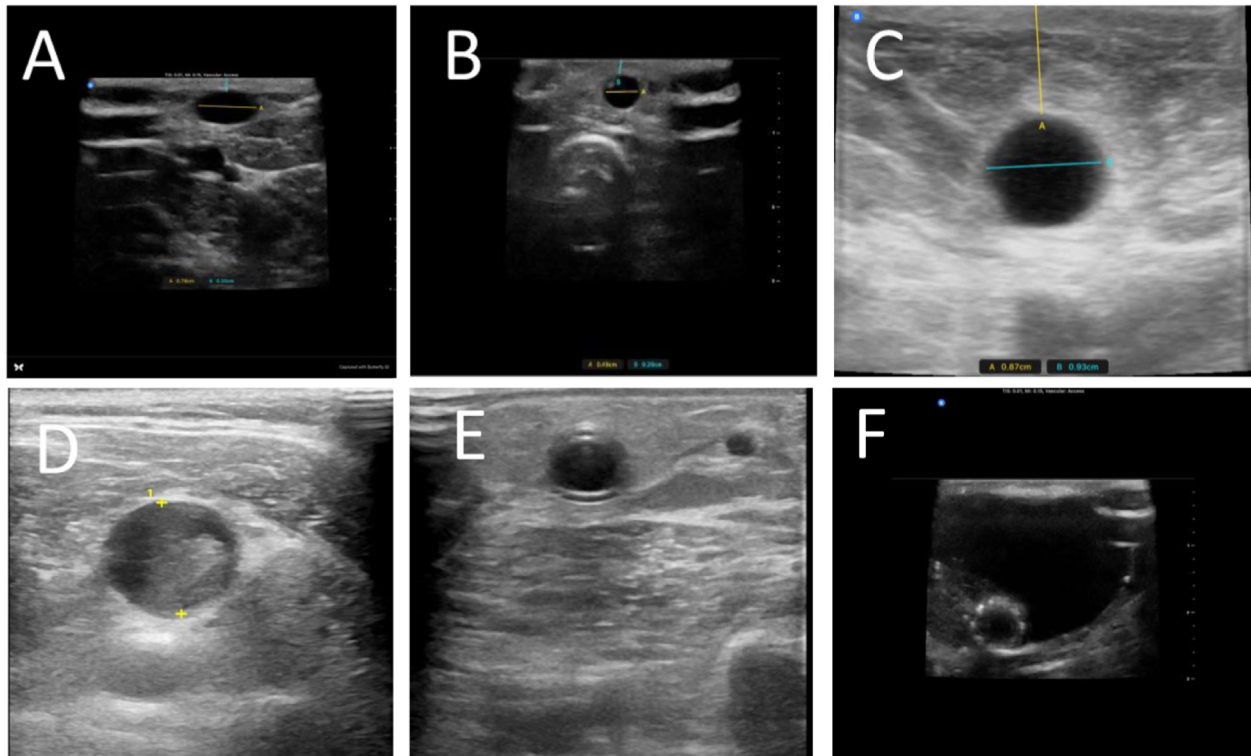
- Coritsidis GN, Machado ON, Levi-Haim F, Yaphe S, Patel RA, Depa J. Point-of-care ultrasound for assessing arteriovenous fistula maturity in outpatient hemodialysis. *J Vasc Access*. 2020;21(6):923-930. doi:10.1177/1129729820913437
- Dua Niyyar V, Buch K, Rawls F, Broxton R. Effectiveness of ultrasound-guided cannulation of AVF on infiltration rates: a single center quality improvement study. *J Vasc Access*. 2023;24(2):322-328. doi:10.1177/11297298211034280
- Kumbar L, Soi V, Adams E, Brown Deacon C, Zidan M, Yee J. Coronal mode ultrasound guided hemodialysis cannulation: a pilot randomized comparison with standard cannulation technique: image guided hemodialysis access cannulation. *Hemodial Int*. 2018;22(1):23-30. doi:10.1111/hdi.12535
- Luehr A. Use of ultrasound guidance during cannulation of arteriovenous fistulas. *Nephrol Nurs J*. 2018;45(5):423-434.
- Robbin ML, Greene T, Allon M, et al. Prediction of arteriovenous fistula clinical maturation from post-operative ultrasound measurements: findings from the Hemodialysis Fistula Maturation Study. *J Am Soc Nephrol*. 2018;29(11):2735-2744. doi:10.1681/ASN.2017111225 ★ESSENTIAL READING
- Schoch ML, Currey J, Orellana L, Bennett PN, Smith V, Hutchinson AM. Point-of-care ultrasound-guided cannulation versus standard cannulation in haemodialysis vascular access: protocol for a controlled random order crossover pilot and feasibility study. *Pilot Feasibility Stud*. 2018;4:176. doi:10.1186/s40814-018-0370-9
- Ward F, Faratro R, McQuillan RF. Ultrasound-guided cannulation of the hemodialysis arteriovenous access. *Semin Dial*. 2017;30(4):319-325. doi:10.1111/sdi.12603

**Sonography in Volume Assessment in Patients With Kidney Disease**

**Case 7:** You are seeing a patient in the emergency department with advanced CKD who is complaining of difficulty breathing. On examination the patient's vital signs are stable although the patient is in apparent respiratory distress. The patient's body habitus and clinical condition preclude evaluation of jugular venous pressure, but the lung sounds are clear. Lower extremity examination reveals bilateral trace pitting edema to the knees with chronic venous stasis changes noted.

**Question 9: Which of the following lung ultrasound findings would be most consistent with cardiogenic pulmonary edema in this patient?**

- (a) A-lines in all lung fields
- (b) An anechoic area superior to the diaphragm on the left side only
- (c) Greater than 3 B-lines in 2 intercostal spaces, bilaterally



**Figure 6.** Ultrasound images of hemodialysis access by point-of-care ultrasound. (A) Mature AVF with adequate depth and diameter. (B) Immature AVF with inadequate diameter but acceptable depth. (C) Immature AVF with adequate diameter but too deep. (D) Thrombosed AVF. (E) AVG with characteristic parallel echogenic lines. (F) Transverse view of stent visible within an aneurysmal hemodialysis access. Abbreviations: AVF, arteriovenous fistula; AVG, arteriovenous graft.

#### (d) Hepatization of the lung bilaterally

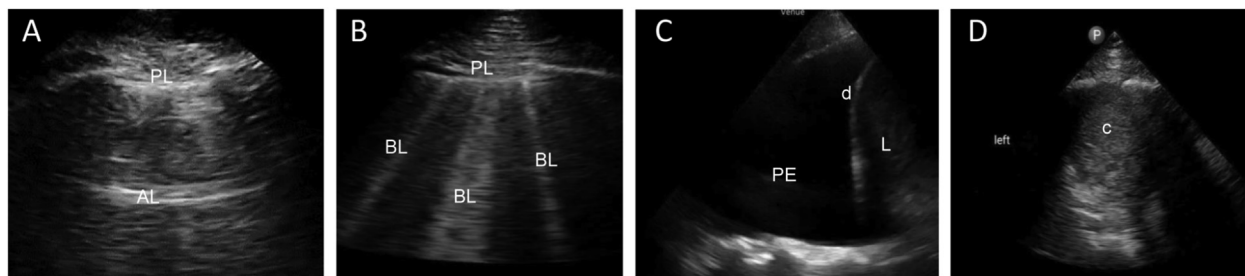
*For the answer to this question, see the following text.*

Nephrologists are frequently asked to evaluate patients with dyspnea and volume overload. Lung ultrasonography (LUS) is a relatively easy skill for nephrologists to learn and can improve diagnostic accuracy. Traditionally, ultrasonography of the lungs was not thought to be feasible because air does not conduct sound well compared with tissue. Over the last 3 decades this view has been questioned and disproven. Reverberation artifacts arising from the pleural surface can yield reliable information about a patient's lung pathology.

LUS is performed by placing the probe with the indicator cephalad in an intercostal space. In research settings, 28 intercostal spaces are examined, but in clinical practice usually fewer zones are scanned. Typically, 4 intercostal spaces on the left and 4 on the right are scanned. When an ultrasound wave meets a normally aerated lung, "A-line" reverberation artifacts (Fig 7A) are seen. A classic study by Lichtenstein et al showed that the A-line pattern had a 90% specificity and a 91% positive predictive value for a pulmonary capillary wedge pressure of less than 13 mm Hg. When an ultrasound wave meets a water-thickened interlobar septa, "B-line" reverberation artifacts (Fig 7B) are

seen. Three B-lines in an intercostal space is a positive "B-region," and 2 B-regions bilaterally represents a "B-line pattern." B-line pattern is 95% specific and 97% sensitive for cardiogenic pulmonary edema in the appropriate clinical context. A recent meta-analysis has shown that LUS has superior sensitivity and specificity for detecting pulmonary edema in patients with decompensated heart failure.

Identifying B-lines is of particular interest in patients on maintenance hemodialysis. Investigations have shown that lung auscultation and dyspnea fail to detect significant extravascular lung water in these patients. Yet lung congestion determined by quantification of B-lines across 28 intercostal spaces predicts mortality above and beyond traditional cardiac risk factors. Follow-up studies have shown that the 28-zone scan can be simplified to an 8-zone scan, which is more practical for the clinician. While promising, 2 randomized control trials failed to show a mortality benefit for LUS-guided dry weight reduction protocols. The Lung Water by Ultrasound-Guided Treatment in Hemodialysis Patients (LUST) Trial enrolled 367 patients receiving hemodialysis at high cardiovascular risk. In the intervention arm, dry weight was adjusted to obtain fewer than 15 B-lines on a 28-zone scan. After a median of 1.5 years of follow-up there was a signal toward improved mortality at the



**Figure 7.** (A) View of normally aerated lung. The pleural line (PL) is seen as well as the first A-line (AL). (B) Image from a patient with pulmonary edema. Note the pleural line as well as 3 B-lines (BL). (C) A large hypoechoic area superior to the diaphragm (d) and liver (L). This hypoechoic area is consistent with a pleural effusion (PE). (D) An area of consolidation (c) that appears similar to the liver.

end of the study, but it failed to meet statistical significance.

There were 2 notable points regarding the results of the LUST Trial. First, there were statistically significantly fewer episodes of intradialytic hypotension (IDH) in the intervention arm. Second, a post hoc analysis showed a decrease in repeat hospitalizations for volume overload. The LUST Trial data suggested that LUS-driven protocols can help clinicians probe target weights without subjecting patients to symptoms of IDH. It is possible that future studies with a longer duration of follow-up will demonstrate a mortality benefit. Despite the findings of the LUST Trial, LUS remains a potential tool in patients receiving hemodialysis primarily because of its role in diagnosing the etiology of a patient's dyspnea.

The correct application of LUS requires knowledge of more than A-lines and B-lines. Nephrologists must know how to identify consolidation, pleural effusions, and pneumothorax. Pneumonia has a variety of appearances on LUS, but classically a lobar consolidation will appear like “tissue” above the diaphragm and is referred to as “hepatization of the lung.” Pleural effusions will appear as an anechoic space above the diaphragm. The subtleties and specifics of LUS are beyond the scope of this curriculum but are a key part of any POCUS training program. Some key lung ultrasound findings are presented in [Figure 7](#). In this patient, the presence of the B-line pattern is both sensitive and specific for pulmonary edema without clinical evidence of pneumonia. Thus, the correct answer is (c), more than 3 B-lines in 2 intercostal spaces, bilaterally.

#### Additional Readings

- Chiu L, Jairam MP, Chow R, et al. Meta-analysis of point-of-care lung ultrasonography versus chest radiography in adults with symptoms of acute decompensated heart failure. *Am J Cardiol.* 2022;174:89-95. doi:10.1016/j.amjcard.2022.03.022
- Lichtenstein DA. Lung ultrasound in the critically ill. *Ann Intensive Care.* 2014;4(1):1. doi:10.1186/2110-5820-4-1 ★ESSENTIAL READING

- Lichtenstein DA, Mezière GA, Lagoueyte JF, Biderman P, Goldstein I, Gepner A. A-lines and B-lines: lung ultrasound as a bedside tool for predicting pulmonary artery occlusion pressure in the critically ill. *Chest.* 2009;136(4):1014-1020. doi:10.1378/chest.09-0001
- Siritopol D, Onofriescu M, Voroneanu L, et al. Dry weight assessment by combined ultrasound and bioimpedance monitoring in low cardiovascular risk hemodialysis patients: a randomized controlled trial. *Int Urol Nephrol.* 2017;49(1):143-153. doi:10.1007/s11255-016-1471-0
- Torino C, Gargani L, Sicari R, et al. The agreement between auscultation and lung ultrasound in hemodialysis patients: the LUST study. *Clin J Am Soc Nephrol.* 2016;11(11):2005-2011. doi:10.2215/cjn.03890416
- Torino C, Tripepi R, Loutradis C, et al. Can the assessment of ultrasound lung water in haemodialysis patients be simplified? *Nephrol Dial Transplant.* 2021;36(12):2321-2326. doi:10.1093/ndt/gfaa285
- Zoccali C, Torino C, Mallamaci F, et al. A randomized multicenter trial on a lung ultrasound-guided treatment strategy in patients on chronic hemodialysis with high cardiovascular risk. *Kidney Int.* 2021;100(6):1325-1333. doi:10.1016/j.kint.2021.07.024
- Zoccali C, Torino C, Tripepi R, et al. Pulmonary congestion predicts cardiac events and mortality in ESRD. *J Am Soc Nephrol.* 2013;24(4):639-646. doi:10.1681/ASN.2012100990 ★ESSENTIAL READING

**Case 8:** You are called to the intensive care unit to evaluate your patient, who is on maintenance hemodialysis. During his hemodialysis session, the patient's systolic blood pressure decreased from 120 mm Hg to 85 mm Hg, and the patient began to feel cool and clammy. The patient was rinsed back and began to feel better. You suspect that you need to make a better assessment of the patient's volume status with focused cardiac ultrasonography (FOCUS), which includes measurement of the inferior vena cava (IVC).

**Question 10:** Which of the following statements regarding POCUS-based volume assessment is true?

- (a) FOCUS has not been shown to improve diagnostic accuracy.

- (b) An IVC diameter measurement in a patient with increased intra-abdominal pressure is an accurate representation of right atrial pressure.
- (c) A small IVC with significant respiratory variation is associated with intradialytic hypotension.
- (d) POCUS cannot be used to evaluate venous excess.

For the answer to this question, see the following text.

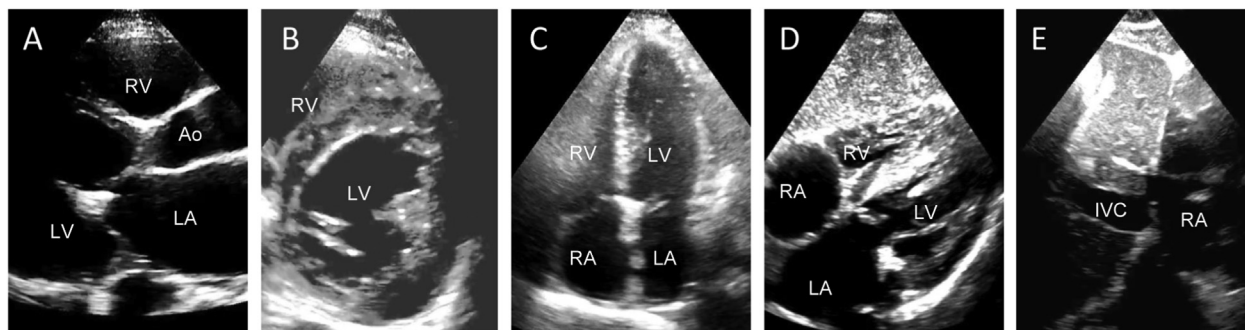
Volume assessment, including assessment of venous congestion, can be challenging with a traditional physical examination. FOCUS is a cutting-edge diagnostic tool that can help nephrologists diagnose volume disorders. FOCUS is taught in medical schools, internal medicine residency programs, and is an important skill in both emergency medicine and critical care medicine. Several professional societies including the Society of Hospital Medicine and the Alliance for Academic Internal Medicine have put out position statements supporting the use of FOCUS. A review by Bhagra et al in 2016 found that POCUS of the heart and lungs had superior sensitivity and similar specificity for identifying volume overload compared with traditional physical examination. A more recent review in the *New England Journal of Medicine* by Díaz-Gómez et al in 2021 reported that FOCUS had high specificity for systolic dysfunction but limited sensitivity. FOCUS has become an established part of clinical volume assessment and is therefore important to the practice of nephrology.

Focused echocardiography includes 4 basic views of the heart, including the IVC (Fig 8). Using the 4 views, nephrologists can assess pericardial effusion, left ventricular contractility, and right ventricular overload. To perform FOCUS, a phased array probe is used. The probe is placed adjacent to the sternum on the left side with the indicator pointing to the right shoulder (parasternal long axis). The probe is then rotated to the left shoulder (parasternal short axis). Next, the probe is placed at the point of maximal

impulse with the indicator to the left axilla (apical 4 chamber). Finally, the probe is placed underneath the xiphoid process (subxiphoid 4 chamber). The IVC is seen through the subxiphoid 4-chamber view. When imaging the IVC, it is important not to mistake the aorta for the IVC. The IVC will be seen within the liver and will connect with the hepatic vein before entering the right atrium. The IVC can be measured in the longitudinal plane or in the transverse plane. When measuring in the longitudinal plane it is important to scan through and identify the greatest diameter to avoid foreshortening the image. In some cases, the subxiphoid approach to IVC is unattainable due to abdominal distention or bowel gas. In these instances, an axillary approach can be used. More details on technique can be found in the additional readings.

Ultrasound measurement of the IVC has long been used to gauge intravascular volume. In patients who are spontaneously breathing, an IVC diameter < 2.1 cm with greater than 50% collapse following a quick inspiration (sniff) is associated with a low right atrial pressure. On the other hand, an IVC > 2.1 cm with less than 50% collapse after sniff is associated with a high right atrial pressure. However, IVC measurement is fraught with limitations. Mechanical ventilation and increased abdominal pressure are two examples of variables that also impact IVC size.

There are some data that have focused on the measurement of IVC specifically in patients with kidney disease. Kaptein et al have written extensively on IVC size in critically ill patients with kidney disease and found that low IVC variability is associated with higher likelihood of achieving the desired ultrafiltration goal. A study by da Hora Passos et al looked at a combination of IVC and lung ultrasound profiles. They found that the presence of significant IVC variation was associated with intradialytic hypotension and discontinuation of dialysis. Another study by Velez et al found that IVC measurement can be helpful



**Figure 8.** (A) Parasternal long axis view showing the RV, Ao, LA, and LV. This view is useful for estimating the size of the RV and LA and for estimating LV systolic function. (B) Parasternal short axis view showing the LV and part of the RV. This view is useful for estimating LV systolic function and RV overload. (C) Apical 4-chamber view showing the LV, LA, RA, and RV. This view is useful for estimating RV and LV relative size, identifying segmental abnormalities and pericardial effusions. (D and E) Views from the subxiphoid 4-chamber view. When the probe is rotated, a transverse cut of the IVC is seen entering the RA. This view is useful for identifying pericardial effusions, estimating LV function, and measuring the IVC. Abbreviations: Ao, aorta; IVC, inferior vena cava; LA, left atrium; LV, left ventricle; RA, right atrium; RV, right ventricle.

in diagnosing and managing acute kidney failure in patients with liver disease.

FOCUS has more to offer than just IVC measurement. Acquiring and interpreting images of the 4 cardiac chambers and identifying pericardial effusions are all within the capabilities of appropriately trained clinicians, including nephrologists. There are very limited data on FOCUS in patients with kidney disease, excluding IVC measurement. One notable study by Lohani et al showed that nephrologists can reliably rule out systolic dysfunction in an outpatient hemodialysis population. A small IVC with significant variability throughout the respiratory cycle has been associated with IDH and dialysis discontinuation.

A comprehensive POCUS-based volume assessment should include both LUS and FOCUS. LUS answers questions about extravascular lung water while FOCUS answers questions about cardiac filling pressures and intravascular volume. Neither FOCUS nor LUS are particularly useful for diagnosing venous pressure excess. Venous pressure is an important determinant of kidney perfusion, so it is important for nephrologists to identify. Some patients may have normal left ventricular contractility, dry lungs, and yet still have significant venous congestion that would benefit from volume removal. The trouble is that venous pressure excess is traditionally difficult to diagnose. Bedside ultrasound with pulse-wave Doppler can help nephrologists quantify venous excess.

Investigators have recently developed the Venous Excess Ultrasound Assessment (VEXUS) score. The VEXUS score is obtained by first measuring the IVC. If the IVC is dilated, then hepatic venous waveforms are obtained with electrocardiogram tracings. Next, portal vein pulsatility is measured. Finally, the intralobar renal arterial and venous waveforms are imaged. An objective scoring system from these 3 exams is graded 0 to 3, with grade 3 being the most severely congested. The seminal work by Beaubien-Souligny et al which first described this system showed that severe congestion was strongly predictive of acute kidney injury in patients undergoing cardiac surgery. A recent and comprehensive literature review by Deschamps et al concluded that a high VEXUS score is consistently associated with kidney dysfunction. There is good evidence that VEXUS can be used to diagnose venous pressure excess.

Several cases and case series have been published where nephrologists have used serial VEXUS examinations to help guide ultrafiltration or diuretic prescription. However, randomized controlled trials comparing VEXUS-guided volume management to the current standard of care have not been performed. Thus, the correct answer is (c), a small IVC with significant respiratory variation is associated with intradialytic hypotension.

### Additional Readings

- Beaubien-Souligny W, Rola P, Haycock K, et al. Quantifying systemic congestion with point-of-care

ultrasound: development of the venous excess ultrasound grading system. *Ultrasound J*. 2020;12(1):16. doi:10.1186/s13089-020-00163-w

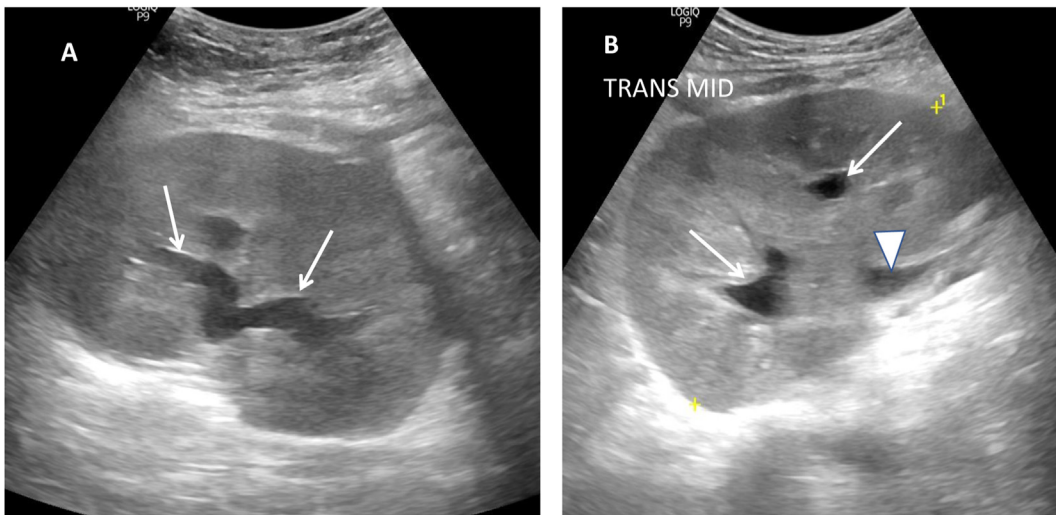
- Bhagra A, Tierney DM, Sekiguchi H, Soni NJ. Point-of-care ultrasonography for primary care physicians and general internists. *Mayo Clin Proc*. 2016;91(12):1811-1827. doi:10.1016/j.mayocp.2016.08.023
- Bianchi Bosisio NSM, Romero-González G, De Silvestri A, Husain-Syad F, Ferrari F. Doppler-based evaluation of intrarenal venous flow as a new tool to predict acute kidney injury: a systematic review and meta-analysis. *Nefrologia*. Published online March 17, 2023. doi:10.1016/j.nefro.2023.03.002 ★ESSENTIAL READING
- Da Hora Passos R, Caldas J, Ramos JGR, et al. Ultrasound-based clinical profiles for predicting the risk of intradialytic hypotension in critically ill patients on intermittent dialysis: a prospective observational study. *Crit Care*. 2019;23(1):389. doi:10.1186/s13054-019-2668-2
- Deschamps J, Denault A, Galarza L, et al. Venous Doppler to assess congestion: a comprehensive review of current evidence and nomenclature. *Ultrasound Med Biol*. 2023;49(1):3-17. doi:10.1016/j.ultrasmedbio.2022.07.011
- Díaz-Gómez JL, Mayo PH, Koenig SJ. Point-of-care ultrasonography. *N Engl J Med*. 2021;385(17):1593-1602. doi:10.1056/NEJMr1916062 ★ESSENTIAL READING
- Kaptein M, Kaptein J, Oo Z, Kaptein E. Relationship of inferior vena cava collapsibility to ultrafiltration volume achieved in critically ill hemodialysis patients. *Int J Nephrol Renovasc Dis*. 2018;11:195-209. doi:10.2147/ijnrd.s165744
- Lohani S, Annadanam S, Martire C, et al. Point-of-care ultrasound for evaluation of systolic heart function in outpatient hemodialysis units. *Kidney Med*. 2021;3(2):317-319. doi:10.1016/j.xkme.2020.11.018
- Velez JCQ, Petkovich B, Karakala N, Huggins JT. Point-of-care echocardiography unveils misclassification of acute kidney injury as hepatorenal syndrome. *Am J Nephrol*. 2019;50(3):204-211. doi:10.1159/000501299

### Sonography in Assessment of Kidney Transplant

**Case 9:** You have been treating a patient who received a kidney transplant. Six months after transplantation, this patient's serum creatinine level increased, and a sonogram was performed by the nephrologist in the transplant clinic (Fig 9). The kidney had a rounded shape, and the cortex was expanded, obliterating the renal sinus fat. This appearance is indicative of inflammation and/or edema. There is also some mild dilatation of the major calyces, and the proximal ureter is visible (arrowhead). The bladder was not dilated.

### Question 11: Which of the following is true?

- (a) This sonogram is diagnostic of acute rejection.
- (b) The sonogram is usually abnormal in acute rejection.



**Figure 9.** (A) Longitudinal and (B) transverse images of the transplanted kidney. Arrows indicate dilated calyces; arrowhead indicates the proximal ureter.

- (c) Resistive index is useful in diagnosing acute rejection.
- (d) Mild hydronephrosis can be seen in transplanted kidneys in the absence of obstruction.

*For the answer to this question, see the following text.*

The sonographic findings described here are nonspecific and can also be seen in acute tubular necrosis, pyelonephritis, viral infection, and recurrent glomerulonephritis, which can usually be ruled out clinically. However, the kidney is sonographically normal in most cases of acute rejection. As in native kidneys, the resistive index is determined mostly by extrarenal factors, and when indicative of intrarenal pathology it is nonspecific. The collecting system is commonly visualized in transplanted kidneys, likely because of proximity to the ultrasound probe as well as reflux from the bladder due to the ectopic insertion of the ureter. Also, ureteral stents are commonly placed during transplantation, providing a direct conduit for urine back to the kidney. The degree of hydronephrosis in this patient does not cause renal failure and would not explain the cortical expansion. Dilatation extending to the minor calyces usually indicates clinically significant hydronephrosis. Thus, the correct answer is (d), mild hydronephrosis can be seen in transplanted kidneys in the absence of obstruction.

**Case 9, continued:** *Immediate clinical correlation expedited the biopsy, which was performed immediately after the sonogram. This led to a timely diagnosis of rejection and institution of therapy before the end of the day.*

**Case 10:** *A 66-year-old man with a kidney transplant presents with acute renal failure, and a bedside sonogram shows moderate hydronephrosis (Fig 10).*

**Question 12: What is the likely cause of the hydronephrosis in this patient?**

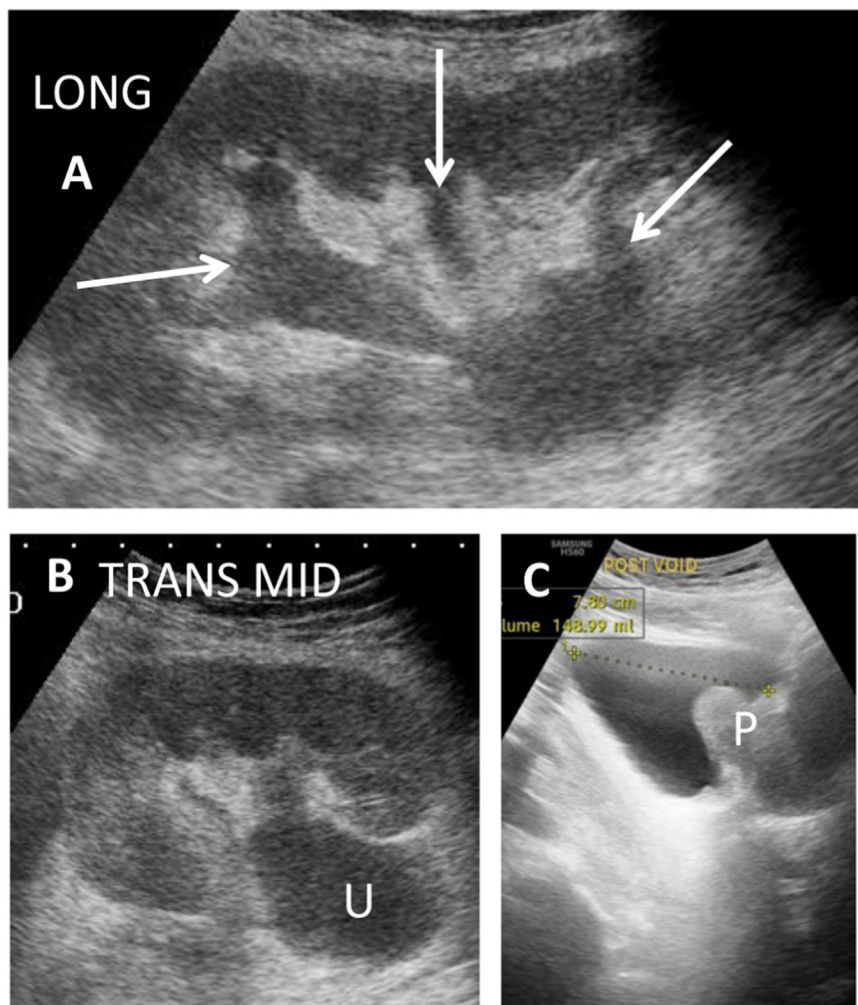
- (a) Ureteral stricture.
- (b) Stenosis at the ureteropelvic junction (UPJ).
- (c) Bladder outlet obstruction.
- (d) Occluded ureteral stent.

*For the answer to this question, see the following text.*

All of the above can cause urinary obstruction in transplant patients. The sonogram in this patient shows dilatation of minor and major calyces, along with marked dilatation of the proximal ureter. Because of the proximity of the ureter to the probe and the lack of obscuring overlying bowel, a dilated collecting system can often be visualized all the way to the bladder, usually revealing the cause of the obstruction. In this case the dilated ureter, which could be followed to the bladder in other images, rules out UPJ obstruction. This and ureteral strictures are uncommon with current surgical techniques.

There is no fluid collection consistent with a lymphocele, and this is an uncommon cause now that stents are routinely placed during surgery. Occlusion of stents should always be considered when they are present, which is not the case in this patient.

Bladder retention is common in transplant patients, due in part to neurogenic bladder from diabetes. In this patient, there was bladder outlet obstruction due to prostatic hypertrophy, with a postvoid volume of 160 mL (a postvoid volume of >50 mL is considered significant). Prompt insertion of a Foley catheter reversed the hydronephrosis and renal failure. Thus, the correct answer is (c), bladder outlet obstruction.



**Figure 10.** Longitudinal (A) and transverse (B) images of the transplanted kidney showing dilated calyces (arrows) and dilated ureter (U). (C). Sagittal view of the postvoid urinary bladder and prostate gland (P).

### Additional Readings

- Choate HR, Mihalko LA, Choate BT. Urologic complications in renal transplants. *Transl Androl Urol.* 2019;8(2):141-147. doi:10.21037/tau.2018.11.13.
- O'Neill WC. Renal resistive index: a case of mistaken identity. *Hypertension.* 2014;64:915-917. doi:10.1161/hypertensionaha.114.04183
- O'Neill WC, Baumgarten DA. Ultrasonography in renal transplantation. *Am J Kidney Dis.* 2002;39:663-678. doi:10.1053/ajkd.2002.31978

### Conclusion

As illustrated by these clinical cases, ultrasonography is an essential tool throughout the spectrum of kidney disorders and their sequelae. It improves diagnostic capabilities, enhances procedural guidance, and optimizes management of the patient with kidney disease. Though many medical schools and residency and fellowship training programs

are now incorporating sonography into their curriculums, only some nephrology programs offer training in performance and interpretation of sonograms. There are an increasing number of introductory sessions at national nephrology meetings that provide a combination of didactic and hands-on training; and as more nephrologists are trained, we hope that sonography will become an integral component of nephrology training.

The American Society of Diagnostic and Interventional Nephrology has recognized the need for maintaining stringent quality criteria in these areas. It now offers certification for physicians in 3 core areas relevant to nephrologists: (1) evaluation of kidneys and bladder, (2) volume assessment, and (3) dialysis access. The certification aims to ensure adherence to exacting benchmarks and also to provide support to fledgling programs with their local regulatory bodies because the issues related to incorporation of ultrasound into busy clinical practices, patient flow, reimbursement, credentialing, and privileges vary widely.

In summary, POCUS has many advantages in that it is mobile, widely available, provides both anatomical and functional assessments while avoiding exposure to both contrast and radiation, is noninvasive, and is relatively inexpensive. Its applications are manifold and span the spectrum of clinical nephrology, optimizing care for the patient with kidney disease. Although image acquisition and interpretation are time-consuming and can be dependent on operator expertise, standardized training leading to proficiency is relatively easy to obtain and will overcome these limitations. The future is literally and figuratively in our hands, and we hope that nephrologists will soon incorporate POCUS into their armamentarium.

### Article Information

**Authors' Full Names and Academic Degrees:** Vandana Dua Niyyar, MD, Daniel W. Ross, MD, and W. Charles O'Neill, MD.

**Authors' Affiliations:** Division of Nephrology, Department of Medicine, Emory University, Atlanta, Georgia (VDN, CO); and

Division of Kidney Diseases and Hypertension, Donald and Barbara Zucker School of Medicine, Hofstra University/Northwell Health, Hempstead, New York (DWR).

**Address for Correspondence:** Vandana Dua Niyyar, MD, Division of Nephrology, Department of Medicine, Emory University, Woodruff Memorial Research Building, Rm 338, 1639 Pierce Dr, Atlanta, GA 30322. Email: [vnnyyar@emory.edu](mailto:vnnyyar@emory.edu)

**Support:** None.

**Financial Disclosure:** Dr Niyyar is the president of the American Society of Diagnostic and Interventional Nephrology, has served as a consultant for Medtronic, Eversana, HMP Education, and BD, and serves on the board of directors for the Kidney Health Initiative and the editorial board for Elsevier ClinicalKey. Dr O'Neill derives income from training courses and educational material related to ultrasonography and receives royalties from UpToDate. Dr Ross declares that he has no relevant financial interests.

**Peer Review:** Received March 13, 2023, in response to an invitation from the journal. Evaluated by 2 external peer reviewers and a member of the Feature Advisory Board, with direct editorial input from the Feature Editor and a Deputy Editor. Accepted in revised form September 7, 2023.